



# Extracranial Head and Neck Schwannomas

## Original Investigation

✉ Mehmet Birinci<sup>1</sup>, ✉ Gökçe Aydın Balaban<sup>2</sup>, ✉ Oğuzhan Okcu<sup>3</sup>, ✉ Oğuz Gül<sup>4</sup>,  
✉ Tuğba Yemiş<sup>1</sup>, ✉ Metin Çeliker<sup>1</sup>, ✉ Özlem Çelebi Erdivanlı<sup>1</sup>

<sup>1</sup>Recep Tayyip Erdoğan University Faculty of Medicine, Department of Otorhinolaryngology, Rize, Türkiye

<sup>2</sup>Rize State Hospital, Clinic of Otorhinolaryngology, Rize, Türkiye

<sup>3</sup>Recep Tayyip Erdoğan University Faculty of Medicine, Department of Pathology, Rize, Türkiye

<sup>4</sup>Haçkalı Baba State Hospital, Clinic of Otorhinolaryngology, Trabzon, Türkiye

## Abstract

**Objective:** Schwannomas are benign tumors originating from the nerve sheath. Extracranial schwannomas account for 25-45% of schwannomas in the head and neck region. This study aimed to evaluate the clinical presentation, diagnostic modalities, and postoperative outcomes of extracranial non-vestibular head and neck schwannomas and to discuss the findings in the context of the literature.

**Methods:** Medical records of patients who underwent surgical treatment for extracranial schwannomas between 2014 and 2022 were retrospectively reviewed. A total of 25 patients met the inclusion criteria and were included in the study.

**Results:** The mean age of the patients was 49 years, with a male-to-female ratio of 16/9. The most common presenting symptom was painless swelling. The face was the most affected site, followed by the oropharynx and scalp. Preoperative imaging was performed in nine patients, with ultrasound being the preferred modality. Preoperative biopsy was conducted in only two patients. The mean follow-up duration was 54 months, with no reported recurrences.

**Conclusion:** This study represents the largest national series of extracranial head and neck schwannomas, providing valuable insights into their clinical presentation, diagnostic approach, and long-term outcomes.

**Keywords:** Head and neck neoplasms, schwannoma, benign neoplasms, peripheral nervous system neoplasms, surgical procedures, treatment outcome

### ORCID IDs of the authors:

M.B. 0000-0001-8184-7454  
G.A.B. 0000-0002-2042-3874  
O.O. 0000-0001-7481-4718  
O.G. 0000-0003-4626-0820  
T.Y. 0000-0001-8713-0251  
M.Ç. 0000-0002-9833-402X  
Ö.Ç.E. 0000-0001-9245-1551

**Cite this article as:** Birinci M, Aydın Balaban G, Okcu O, Gül O, Yemiş T, Çeliker M, et al. Extracranial head and neck schwannomas. Turk Arch Otorhinolaryngol. [Epub Ahead of Print]

This study was originally presented as an oral presentation at the 8<sup>th</sup> Spring Meeting of the TKBBV, held in Antalya on April 27, 2023.

**Corresponding Author:**  
Mehmet Birinci, MD;  
mehmet.birinci@erdogan.edu.tr

**Received Date:** 20.12.2024

**Accepted Date:** 25.02.2025

**Epub:** 16.04.2025

**DOI:** 10.4274/tao.2025.2024-12-3

## Introduction

Schwannomas are tumors that originate from Schwann cells. They typically arise from peripheral, cranial, and autonomic nerves, except for the olfactory and optic nerves (1). However, recent case reports have described schwannomas in these two nerves, challenging the long-standing belief that they do not develop in this location (2,3). This underscores

the need to consider schwannomas in the differential diagnosis of lesions in all areas of the head and neck region where nerve cells are present, including the cranial nerves.

The clinical signs and symptoms of schwannomas depend on the tumor's location, size, and nerve of origin. Surgical excision is the primary treatment modality; however, complete removal may



not always be feasible without compromising the function of the affected nerve (4).

This study aimed to collect clinical findings, radiological, and pathological characteristics of extracranial non-vestibular head and neck schwannomas. By focusing on this specific subgroup, this study provides valuable insights into their diagnosis, management, and surgical outcomes, contributing to a better understanding of these rare tumors.

Methods

Ethical approval for this study was obtained from the Ethics Committee of Recep Tayyip Erdoğan University Non-Interventional Clinical Research (approval no: 2022/234, date: 22.12.2022). The study was conducted in accordance with the principles outlined in the Declaration of Helsinki. Medical records of patients with histopathologically confirmed extracranial head and neck schwannomas, treated at the Department of Otorhinolaryngology of Recep Tayyip Erdoğan University Training and Research Hospital between 2014 and 2022, were retrospectively reviewed. Patients were excluded if they had intracranial schwannomas, schwannomas located outside the head and neck region, or if surgery was performed in a non-ear, nose, and throat (ENT) department such as plastic and reconstructive surgery. All patients provided informed consent for the use of their anonymized data in this study.

In our clinic, preoperative evaluations are guided by the following algorithm: superficial, regularly shaped lesions with a benign appearance are not subjected to radiologic imaging. Deep-seated lesions, those with suspected malignancy, or unilateral lesions in the nasal cavity are assessed using appropriate imaging modalities. Ultrasound is the first-line imaging technique for neck lesions, while magnetic resonance imaging (MRI) is preferred for lesions suspected of malignancy or those located in the nasal cavity. Biopsy is performed only for lesions demonstrating radiologic features suggestive of malignancy. Therefore, in addition to patient demographics, presenting symptoms, and anatomical tumor location, we recorded the imaging modality or biopsy procedure, if performed. Finally, follow-up duration and recurrence status were documented.

Statistical Analysis

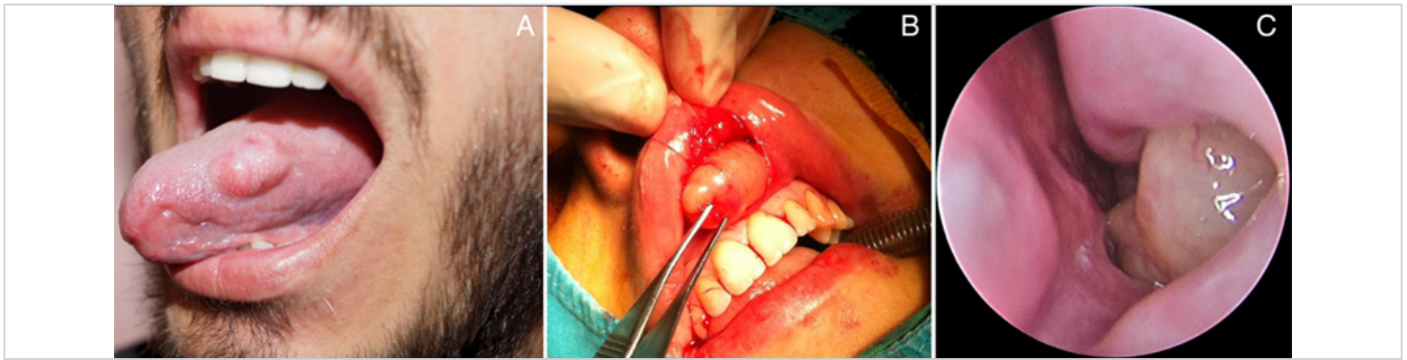Statistical analysis was performed with IBM SPSS Statistics, Version 22.0 (IBM SPSS Statistics for Windows, Armonk, NY: USA). Descriptive statistics were presented as median (minimum-maximum) for age and follow-up duration, or number (percent -%) for gender, complaints, localization, imaging and preoperative biopsy.

Results

Records of 143 patients diagnosed with schwannoma were reviewed for the study. Of these, 73 had schwannomas located outside the head and neck region, 41 had acoustic (vestibular) schwannomas, and 4 had undergone surgery in non-ENT departments. Thus, 118 patients who did not meet the inclusion criteria were excluded. Demographic characteristics of the included patients are summarized in Table 1. Briefly, two patients were pediatric cases (aged 9 and 13 years), and four patients were over 65 years of age. Two-thirds of the lesions were located on the face, followed by the oropharynx and the scalp. Among facial lesions, four were located around the right eyebrow, one around the left eyebrow, and one on the right chin. In the oropharynx, four lesions were located on the tongue and one on the palate. Neck lesions were situated in the submandibular region and at level IV. In the oral cavity, two lesions were found on the lower lip and one on the upper lip.

Figure 1 presents schwannomas at various anatomical sites, emphasizing the importance of appropriate preoperative imaging. A well-circumscribed, superficial mass on the tongue (Figure 1a) and an encapsulated lesion on the upper lip (Figure 1b) were completely excised without the need for preoperative imaging or biopsy. A left-sided sinonasal schwannoma was excised following MRI and biopsy (Figure 1c).

Table 1. Demographic and clinical characteristics of the study population. Data presented as mean (range) or number (%)	
Parameter	Patients (n=25)
Age, years	49 (9-90)
Gender, (n%)	Male: 16 (64%)
	Female: 9 (36%)
Complaints and localizations, (n%)	
Painless swelling (n=22)	Face (n=6, 24%)
	Oropharynx (n=4, 16%)
	Scalp (n=5, 20%)
	Neck (n=4, 16%)
	Oral cavity (n=3, 12%)
Nasal obstruction (n=2)	Nasal cavity (n=2, 8%)
Dysphagia (n=1)	Oropharynx (n=1, 4%)
Preoperative imaging, (n%)	Performed: 9 (36%)
Modality, (n%)	USG: 5 (20%)
	MRI: 4 (16%)
Preoperative biopsy, (n%)	Performed: 2 (8%)
	Not performed: 23 (92%)
Follow-up period, months	54 (6-98)
MRI: Magnetic resonance imaging, USG: Ultrasonography	



**Figure 1.** Clinical and intraoperative images of schwannomas located in various regions of the head and neck. **a)** Well-circumscribed lingual schwannoma presenting as a submucosal mass on the tongue. **b)** Intraoperative view of an encapsulated upper lip schwannoma during surgical excision. **c)** Endoscopic image showing a left-sided sinonasal schwannoma located in the inferior meatus

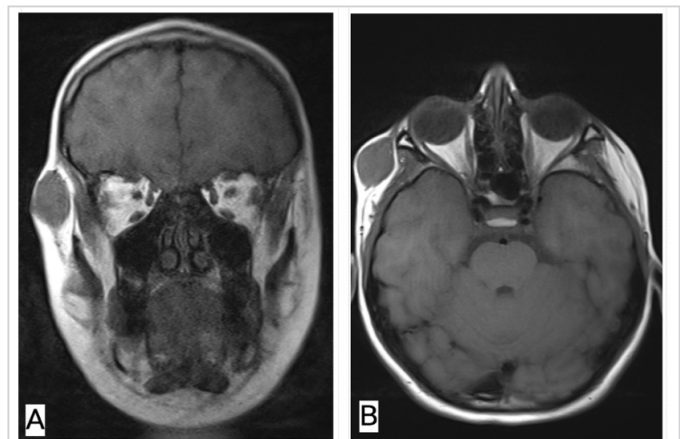
Preoperative imaging was performed in approximately one-third of the patients to support differential diagnosis based on lesion localization. Ultrasound was utilized in three patients with neck lesions and in two patients with scalp lesions due to suspicion of malignancy; all lesions were reported as benign. MRI was preferred in cases requiring deeper tissue evaluation, including two patients with unilateral nasal cavity lesions, one with a tongue lesion, and one with a facial mass in the temporoorbital region. All MRI findings were consistent with benign pathology (Figure 2).

Two patients required preoperative biopsy for definitive diagnosis. One patient with a sinonasal lesion underwent incisional biopsy, while another patient with a neck lesion had a tru-cut biopsy. All patients underwent complete surgical excision, and the specimens were submitted for histopathological analysis. Figure 3 demonstrates the two routinely employed histological techniques. Hematoxylin and eosin staining (Figure 3a) revealed the characteristic biphasic architecture of schwannomas, with Antoni A areas consisting of densely packed spindle cells, and Antoni B areas showing a looser, myxoid stroma. Immunohistochemical staining for S-100 protein (Figure 3b) showed strong and diffuse positivity, confirming the neural crest origin of the tumors.

The mean follow-up duration was 54.3 months, with the longest follow-up period being 98 months and the shortest six months. No clinical, radiological, or histopathological evidence of recurrence was observed during the follow-up period.

## Discussion

This case review demonstrated that extracranial non-vestibular head and neck schwannomas most commonly present as painless, well-circumscribed masses, with the face being the most frequently affected anatomical region. Surgical excision remains the standard treatment, and no recurrences were observed during long-term follow-up.



**Figure 2.** Preoperative magnetic resonance imaging of a schwannoma in the right temporoorbital region, demonstrating a well-defined 32×16×26 mm mass with low signal intensity on T1-weighted sequences **a)** Coronal view **b)** Axial view

The median age of patients in our study was consistent with previously published literature. Schwannomas are known to occur most frequently between the 3<sup>rd</sup> and 4<sup>th</sup> decades of life, with a slight female predominance reported in some studies (5).

In line with our findings, most extracranial schwannomas lack specific findings on physical examination and are often incidentally discovered as painless masses. However, depending on the tumor's size and anatomical location, symptoms such as dysphagia, cough, Horner's syndrome, dyspnea, and hoarseness may occur (6). Similarly, in our study, nasal obstruction was the predominant symptom in patients with nasal cavity involvement, whereas dysphagia was reported in one patient with a tongue base lesion. In rare cases, schwannomas may present as giant masses (7). It has also been noted that these tumors tend to be fixed along the axis of the originating nerve and more mobile in a direction perpendicular to it, a feature that may aid in diagnosis (8).

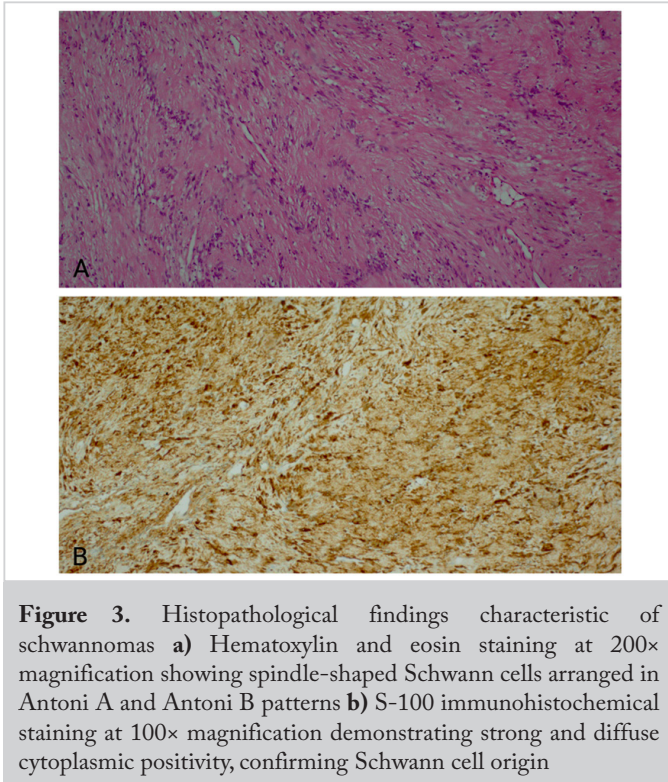
Extracranial schwannomas account for 25-45% of all schwannomas, with the cervical region and oral cavity frequently cited as the most common locations in different studies (9,10). In our study, the face was the most affected site, followed by the oropharynx and the scalp, which slightly

differ from international series reporting the cervical region as the predominant site (11).

Intraoral schwannomas constitute 1-12% of the schwannomas in the head and neck region. In terms of specific subregions, the tongue, the floor of the mouth, the buccal mucosa, the lips, the palate, and the jaw are listed in order of frequency (12). Our findings align with this pattern, though we did not observe any buccal mucosa involvement in our cohort.

Neurogenic tumors in the head and neck region arise from neural crest cells that differentiate into Schwann cells and sympathoblasts. Schwann cells are the main cells of both schwannomas and neurofibromas. Neurofibromas originate from the perineurium and are therefore intimately connected to the nerve from which they arise. Schwannomas, on the other hand, assume a spindle-shaped appearance while longitudinally growing along the nerve without disrupting its structural and functional identity, and can be surgically separated from the nerves from which they originate (13). We could not identify the originating nerve in any of our cases. This may be attributed to the absence of neurological symptoms, which could have provided diagnostic clues. Additionally, no identifiable nerve trunk was observed intraoperatively. All dissections were performed according to good surgical practice.

Similar studies were conducted in our country with smaller case numbers (Table 2). The series by Altuntaş et al. (5) in 2012 is the first one and included 6 cases. The largest series was reported by Balcı et al. (14) consisting of 23 cases. In a series of 31 cases reported from Öztürk et al. (15), 18 patients



**Figure 3.** Histopathological findings characteristic of schwannomas **a)** Hematoxylin and eosin staining at 200× magnification showing spindle-shaped Schwann cells arranged in Antoni A and Antoni B patterns **b)** S-100 immunohistochemical staining at 100× magnification demonstrating strong and diffuse cytoplasmic positivity, confirming Schwann cell origin

**Table 2.** Summary of extracranial schwannoma studies in Türkiye: localization, neurological deficits, and postoperative outcomes

Study	Period	Cases (n)	Localization					Preoperative neurologic deficit	Mean follow-up period (months)	Postoperative sequelae
			Neck	Oral cavity	Face and scalp	Nasal cavity	Middle ear cavity			
Altuntaş et al. (5)	2004-2008	6	3	1	-	1	1	N/A	N/A	Facial paresthesia Hypoesthesia (8) Facial nerve injury (3)
Balcı et al. (14)	2008-2016	23	15	3	4	1	-	Unilateral vocal cord paralysis (1)	17.6	Vagus injury (2) Hypoglossal nerve injury (1) Glossopharyngeal nerve injury (1)
Öztürk et al. (15)	2007-2018	18	12	3	-	-	3	Facial paralysis (3)	21	Seven patients (not described)
Çakır et al. (16)	1995-2015	14	11	1	-	2	-	None	14	Neural deficit (6) not described
Gülşen and Kurt (17)	2015-2019	14	9	4	-	1	-	N/A	12.3	Motor loss in brachial plexus 1 Taste loss 1 Ptosis 1

had an extracranial tumor. Recently, a series of 14 cases by Çakır et al. (16) and another series of 14 cases by Gülşen and Kurt (17) have been published.

Our study stands out as the largest series of extracranial head and neck schwannomas conducted in Türkiye, with longer follow-up compared to previous national studies (5,14-17).

Its retrospective nature is a limitation, as this may potentially introduce selection bias. Additionally, the lack of preoperative neurological deficits in our cohort limited the ability to identify the originating nerves.

## Conclusion

Compared to international studies, our cohort had fewer imaging evaluations, which may reflect differences in institutional protocols and access to imaging modalities. Future prospective, multicenter studies are needed to establish standardized imaging protocols, optimize nerve preservation strategies, and assess long-term functional outcomes in patients with extracranial schwannomas.

## Ethics

**Ethics Committee Approval:** This study was approved by the Non-Interventional Clinical Research Ethics Committee of Recep Tayyip Erdoğan University (approval no: 2022/234, date: 22.12.2022).

**Informed Consent:** All patients provided informed consent for the use of their anonymized data in this study.

## Footnotes

**Information:** The authors acknowledge the use of a large language model (ChatGPT-4o, OpenAI) to refine the language, improve readability, and enhance the academic style of the manuscript following the completion of the initial draft. All modifications were carefully reviewed and validated by the authors to ensure scientific accuracy and adherence to ethical standards.

## Authorship Contributions

Surgical and Medical Practices: M.B., Ö.Ç.E., Concept: M.B., G.A.B., Ö.Ç.E., Design: M.B., G.A.B., O.O. T.Y., M.Ç., Ö.Ç.E., Data Collection and/or Processing: M.B., O.O., O.G., M.Ç., Ö.Ç.E., Analysis and/or Interpretation: M.B., G.A.B., O.G., Literature Search: M.B., O.G., T.Y., M.Ç., Writing: M.B., O.O., O.G., T.Y., M.Ç.

**Conflict of Interest:** The authors declare that they have no conflict of interest.

**Financial Disclosure:** The authors declare that this study has received no financial support.

## Main Points

- Extracranial schwannomas mostly present as painless, well-circumscribed masses, with the face being the most commonly affected region in this study.
- Surgical excision remains the definitive treatment, with no recurrences observed during long-term follow-up.
- Future prospective, multicenter studies are needed to standardize imaging protocols and assess long-term functional outcomes.

## References

1. Wang B, Yuan J, Chen X, Xu H, Zhou Y, Dong P. Extracranial non-vestibular head and neck schwannomas. *Saudi Med J*. 2015; 36: 1363-6. [Crossref]
2. Micovic MV, Zivkovic BM, Zivanovic JD, Bascarevic VL, Bogosavljevic V, Rasulic LG. Ancient olfactory schwannoma - case report and literature review. *Turk Neurosurg*. 2017; 27: 651-6. [Crossref]
3. Vishwakarma R, Maheshwari J, Soni H. Endoscopic excision of optic nerve schwannoma. *Laryngoscope*. 2024; 134: 3102-4. [Crossref]
4. Zhang H, Cai C, Wang S, Liu H, Ye Y, Chen X. Extracranial head and neck schwannomas: a clinical analysis of 33 patients. *Laryngoscope*. 2007; 117: 278-81. [Crossref]
5. Altuntaş E, Bora A, Cerrah Y, Müderris S, Elagöz Ş. Kliniğimizde tedavileri yapılan baş ve boyun schwannomlu olgular. *Cumhuriyet Med J*. 2012; 34: 289-94. [Crossref]
6. Sharma P, Zaheer S, Goyal S, Ahluwalia C, Goyal A, Bhuyan G, et al. Clinicopathological analysis of extracranial head and neck schwannoma: a case series. *J Cancer Res Ther*. 2019; 15: 659-64. [Crossref]
7. Alkan S, Dadaş B. Giant schwannoma cases of neck. *The Medical Bulletin of Sisli Etfal Hospital*. 2007; 41: 47-9. [Crossref]
8. Liu HL, Yu SY, Li GK, Wei WI. Extracranial head and neck Schwannomas: a study of the nerve of origin. *Eur Arch Otorhinolaryngol*. 2011; 268: 1343-7. [Crossref]
9. Leu YS, Chang KC. Extracranial head and neck schwannomas: a review of 8 years experience. *Acta Otolaryngol*. 2002; 122: 435-7. [Crossref]
10. Phulware RH, Sardana R, Chauhan DS, Ahuja A, Bhardwaj M. Extracranial schwannomas of the head and neck: a literature review and audit of diagnosed cases over a period of eight years. *Head Neck Pathol*. 2022; 16: 707-15. [Crossref]
11. Verma P, Riju J, Ramalingam N, Zeinuddeen R, Paulose AA, Susheel S, et al. Extracranial head and neck schwannomas: a single centre retrospective experience of 97 cases. *Indian J Otolaryngol Head Neck Surg*. 2024; 76: 4292-9. [Crossref]
12. Harazono Y, Kayamori K, Sakamoto J, Akaike Y, Kurasawa Y, Tsushima F, et al. Retrospective analysis of schwannoma in the oral

15. Öztürk M, Sirin S, Alekberli FR, Mutlu F, İşeri M. Head and neck schwannomas: a tertiary referral single-centre experience. *ENT Updates*. 2019; 9: 206-12. [Crossref]
16. Çakır A, Erdağ TK, Ecevit MC, Güneri EA, Sütay S, İkiz AÖ. Extracranial head and neck schwannomas: A series of 14 patients. *Tr-ENT*. 2017; 27: 257-63. [Crossref]
17. Gülşen S, Kurt E. Retrospective analysis of extracranial schwannoma of the head and neck region and surgical treatment. *ADYÜ Sağlık Bilimleri Derg*. 2019; 5: 1722-30. [Crossref]