

Huge Rhinolith in Adult

Case Report

Tan Shi Nee¹, Salina H², Primuharsa Putra SHA³

¹KPJ Healthcare University College, Department of Otorhinolaryngology-Head & Neck Surgery, Kuala Lumpur, Malaysia

²Department of Otorhinolaryngology-Head & Neck Surgery, Faculty of Medicine, Universiti Kebangsaan Malaysia Medical Centre, Kuala Lumpur, Malaysia

³Ear, Nose, Throat-Head & Neck Consultant Clinic, KPJ Seremban Specialist Hospital, Seremban, Malaysia

Abstract

Objective: Rhinoliths in adult are rare and uncommon.

Clinical Presentation and Intervention: We present two cases of rhinoliths in adult. The first case reports an interesting case of a healthy adult male who presented with symptoms of foul-smelling nasal discharge and nasal block. The second case report merely shows an adult with the same clinical symptoms in

which a rhinolith was diagnosed. Both cases report incidental findings of huge rhinoliths in the right nasal cavity.

Conclusion: Management of the rhinolith and possible genesis of the rhinolith are discussed.

Keywords: Nose, foreign body, adult

Introduction

Rhinolithiasis is a clinical symptom caused by rhinoliths (1). Today, the incidence of rhinolith in adults is low. Rhinoliths result from mineralization of an endogenous or exogenous nidus and usually develop within the nasal cavity (1). They are a mixture of 10% organic substances and 90% inorganic material incorporated into the lesion from nasal secretions (2). Exogenous rhinoliths are more common and are usually formed due to concretions around impacted foreign bodies (3), whereas endogenous rhinoliths develop spontaneously with deposition of mineral around accumulated secretions (3). The presence of rhinoliths can cause unilateral nasal symptoms, like nasal discomfort or obstruction with or without foul-smelling discharge. The severity of the symptoms depends upon the size of the rhinolith. Long-term complications for rhinoliths include nasal polyps, atrophic rhinitis, septal perforation (4) and oroantral fistula (5).

Diagnosis is established via medical history, anterior rhinoscopy, and nasal endoscopy and is confirmed with radiological imaging (2).

Clinical Presentation and Intervention

Case 1

A 41-year-old Malay man presented with a history of intermittent right foul-smelling nasal discharge

and nasal blockage for 6 weeks. It was not associated with pain and facial swelling. He denied a history of frequent running nose and blocked nose prior to the onset of the current illness. He also denied any history of putting a foreign body inside the nostril during childhood.

Nasal examination using a 0-degree scope revealed an irregular hard mass and friable mucosa situated at the inferior meatus. No mucopurulent was discharge seen. The postnasal space was normal. The oral cavity and neck examination was normal.

Computed tomography of the paranasal sinuses showed widening of the right nasal space with a soft tissue mass seen in the right nasal cavity (Figure 1). The adjacent inferior turbinate was thickened.

He underwent an examination under general anesthesia. Intraoperatively, there were multiple stony hard masses in the right nasal cavity (Figure 2). Upon removal of the rhinolith, the area became widened. The post-operative recovery was uneventful.

The histopathological examination showed calculus tissue. Biopsy from the right inferior turbinate and right inferior meatus showed moderate chronic inflammation. There is no evidence to suggest malignancy.



Address for Correspondence:
Primuharsa Putra Sha, Department of
Otorhinolaryngology-Head & Neck Surgery,
Faculty of Medicine, Universiti Kebangsaan
Malaysia Medical Centre,
Kuala Lumpur, Malaysia
Phone: +606-7677800-1138
E-mail: putrani@yahoo.co.uk
Received Date/Geliş Tarihi: 14.08.2014
Accepted Date/Kabul Tarihi: 25.10.2014

© Copyright 2014 by Official Journal of the Turkish
Society of Otorhinolaryngology and Head and
Neck Surgery Available online at
www.turkarchotolaryngol.net
DOI:10.5152/tao.2014.711

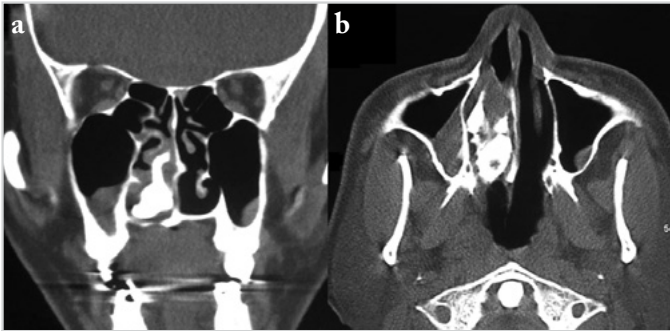


Figure 1. a, b. Widening of the right nasal space with soft tissue mass seen in the right nasal cavity

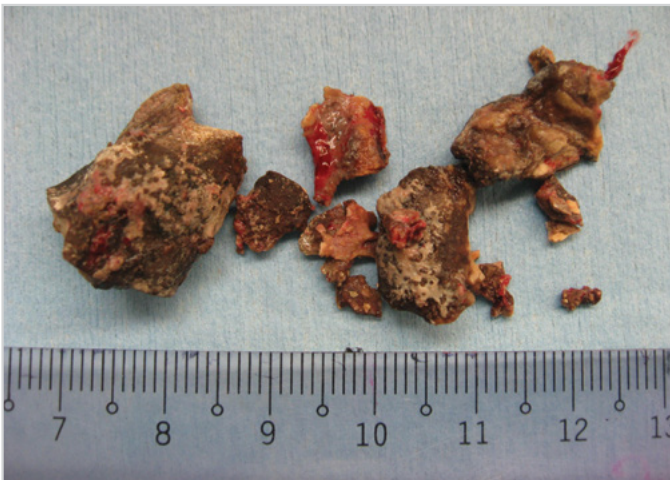


Figure 2. Multiple stony hard masses in the right nasal cavity

Case 2

A 58-year-old Malay lady with no known medical illness presented with right foul-smelling nasal discharge with intermittent nasal blockage. There was no associated facial pain or swelling. She also denied any history of frequent runny nose. Nasal examination using a 0-degree scope revealed an irregular hard mass at the inferior meatus (Figure 3). No mucopurulent discharge was seen. The postnasal space was normal. The oral cavity and neck examination was normal. The patient was advised for further investigation and operative intervention; however, due to logistic reasons, the patient refused.

Discussion

Rhinolith obtained its term from a Greek word, in which rhino = nose and lith = stone (6). It was first coined in 1845 and was described as a partially or completely encrusted foreign body in the nose (7). Rhinolith in adults is considered a rare condition. Balasubramanian reported that for some unknown reason, males seem to be more commonly affected than females (8).

An exogenous source is more common in adults, although exogenous sources of rhinolith have been reported (2, 6, 8). The most common location for rhinoliths in most cases is the inferior nasal meatus (2).

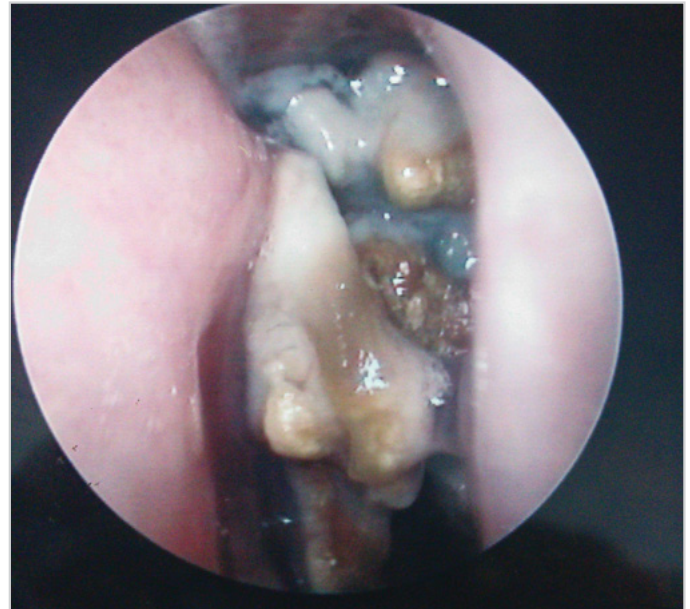

Figure 3. Irregular hard mass and friable mucosa at the inferior meatus

The pathogenesis of the development of rhinoliths is still not completely elucidated (9). However, there are a few theories for its development, which are generally accepted and recognized as cited in the literature (9). For example, a foreign body introduced into the nose must give rise to acute or chronic inflammation of the nasal mucosa, the discharge must have a high content of calcium and/or magnesium, mechanical obstruction blocks the outflow of pus and mucus, the secretion may be exposed to a current of air, thus this concentrate the pus and mucus and permit the mineral salts to precipitate, and eventually give rise to incrustation.

The diagnosis of a rhinolith is usually clinical. The presence of a unilateral obstruction with foul-smelling discharge should raise the suspicion of a rhinolith; however, there are unusual cases of bilateral rhinolithiasis that has been published in the literature (2, 6).

In this case, both of our patients presented with symptoms of intermittent right foul-smelling nasal discharge and nasal blockage for 6 weeks. Both of the patients also denied any history of putting a foreign body inside the nostrils during childhood. Incidental findings usually reveal an irregular mass in the floor of the nasal cavity, commonly the inferior meatus region, via nasoendoscopy (6).

There are other possible differential diagnoses to consider besides a diagnosis of rhinolith; for example, a malignant or benign tumor of the nasal cavity may also be calcified (10). The benign tumor category includes osteoma, calcified polyps, and hemangioma; osteosarcoma and chondrosarcoma are in the malignant category; and syphilis, tuberculosis, and sinusitis are in the inflammatory category.

Radiological imaging, such as computed tomography (CT) scan, helps to distinguish rhinoliths from these entities (10) and also provides information about the exact location, dimension, complications, and other accompanying diseases (10).

Although CT scan is very important for the differential diagnosis of these cases, Ogretmenoglu explained that nasal endoscopy in the diagnosis of rhinolithiasis is a valuable diagnostic tool (7).

The treatment for rhinolith is removal under general anesthesia in view of the concretion's size, irregular surface, and impingement of the right inferior turbinate (2, 6, 10), as discussed in our case. Local anesthesia can be used in the rhinolith removal; however, it is not advisable due to the size and sharp edges of the concretion of the material, which can cause severe pain, massive epistaxis, trauma to the normal structure of the nose, and may results in incomplete removal in view co-operation of the patient is required.

Conclusion

Finally, clinical symptoms of nasal obstruction with foul-smelling nasal discharge should raise a suspicion of rhinolith in an adult, although the incidence is low.

Informed Consent: Written informed consent was not obtained due to the retrospective nature of this study.

Peer-review: Externally peer-reviewed.

Author Contributions: Concept - T.S.N., P.P.S.; Design - P.P.S.; Supervision - P.P.S., S.H.; Materials - S.H., P.P.S.; Data Collection and/or Processing - T.S.N., S.H., P.P.S.; Analysis and/or Interpretation - P.P.S., S.H.; Literature Review - T.S.N., P.P.S.; Writer - T.S.N., P.P.S.; Critical Review - P.P.S.

Conflict of Interest: No conflict of interest was declared by the authors.

Financial Disclosure: The authors declared that this study has received no financial support.

References

1. Yildirim N, Arslanoglu A, Sahan M, Yildirim A. Rhinolithiasis: clinical, radiological and mineralogical features. *Am J Rhinol* 2008; 22: 78. [\[CrossRef\]](#)
2. Kingier A, Kawatra M. Case report: endogenous adult rhinolith. *Indian Journal of Basic and Applied Medical Research* 2014; 3: 17-520.
3. Turan A, Gozu A, Genç B, Dayicioğlu D, Özsoy Z, Yaşar H, et al. A cleft lip/nose deformity and rhinolith. *Plas Reconstr Surgery* 2004; 113: 1079-80. [\[CrossRef\]](#)
4. Kharoubi S. Rhinolithiasis associated with septal perforation. A case report. *Acta Otorhinolaryngol Belg* 1998; 52: 241-5.
5. Flood TR. Rhinolith: an unusual cause of palatal perforation. *Br J Oral Maxillofac Surg* 1988; 26: 486-90. [\[CrossRef\]](#)
6. Irfan M, Khairi M. Unilateral foul smelly nasal discharge in an adult. *Malaysian Family Physician* 7.1 2012; 3.
7. Ogretmenoglu O. The value of endoscopy in the diagnosis of rhinolithiasis: a case report. *Kulak Burun Bogaz Ihtis Derg* 2003; 11: 89-92.
8. Srinivas Moorthy PN, Srivalli M, Rau GV, Prasanth C. Study on clinical presentation of ear and nose foreign bodies. *Indian J Otolaryngol Head Neck Surg* 2012; 64: 31-5. [\[CrossRef\]](#)
9. Brehmer D, Riemann R. Case report: the rhinolith - a possible differential diagnosis of a unilateral nasal obstruction. *Case Rep Med* 2010; 2010: 845671.
10. Orhan K, Kocyigit D, Kisnisci R, Paksoy CS. Rhinolithiasis: an uncommon entity of the nasal cavity. *Oral Surg Oral Med Oral Path Oral Radiol Endod* 2006; 101: 28-32. [\[CrossRef\]](#)