

OLGU BİLDİRİLERİ / CASE REPORTS

Nasopharyngeal tuberculosis: a case report

Ş. Civelek, İ. Sayın, İ. Ercan, B.Ö. Çakır, T. Başak, S. Turgut

Nazofarenks tüberkülozu: olgu sunumu

44 yaşında kadın hasta tek taraflı ağrısız lenf nodları ile başvurdu. Nazofarenksin endoskopik muayenesinde nazofarenks posterior duvarda mukozal düzensizlik saptandı. Nazofarenks ve lenf nodu biyopsisi uygulandı. Biyopsilerin patolojik incelemesinde kazeifikasyon nekrozu içeren granülomatoz enflamasyon saptandı. Aside rezistan bakteri için yapılan direkt boyamada bakteri saptanmadı. Kültür ve polimeraz zincir reaksiyonu (PCR) ile *Mycobacterium tuberculosis* saptandı. Hastaya antitüberküloz tedavi verildi. Semptomlar tedavi sonrası geriledi. Yeni bir nazofarenks tüberkülozu olgusu sunuldu ve tartışıldı. Tüberkülozun nazofarenks patolojilerinin ayırıcı tanısında göz önünde bulundurulması gerekliliği vurgulandı.

Anahtar Sözcükler: Nazofarenks patolojisi, nazofarenks tüberkülozu, nazofarenks, *Mycobacterium tuberculosis*.

Abstract

Forty-four year old female presented with unilateral painless cervical lymph nodes. Endoscopic examination on nasopharynx showed mucosal irregularity on the posterior wall of nasopharynx. The biopsies of nasopharynx and lymph nodes showed granulomatous inflammation with caseation necrosis. Direct stain for acid fast bacilli was negative but culture and polymerase chain reaction (PCR) for *Myobacterium tuberculosis* were found positive. The patient was treated with antituberculosis regimen. Symptoms resolved after medication. A new case of nasopharyngeal tuberculosis was presented and discussed. The consideration of *Mycobacterium tuberculosis* in the differential diagnosis of nasopharyngeal pathology was emphasized.

Key Words: Nasopharyngeal pathology, nasopharyngeal tuberculosis, nasopharynx, *Mycobacterium tuberculosis*.

Türk Otolarengoloji Arşivi, 2008; 46(1): 53-57

Turk Arch Otolaryngol, 2008; 46(1): 53-57

Introduction

M. tuberculosis is still an important general health problem especially in risk groups and endemic areas. Among the different forms of tuberculosis, involvement of nasopharynx is rare.^{1,2} Reviewed patients showed that systemic evaluation for tuberculosis is usually normal and nasopharyngeal involvement mostly occurs as a primary.² The pathophysiology of this distinct form is still unclear. In present report, a new case of nasopharyngeal tuberculosis was presented and discussed.

Şenol Civelek MD; İbrahim Sayın, MD; İbrahim Ercan, MD; Burak Ömür Çakır, MD; Suat Turgut, MD

Department of Otorhinolaryngology -Head and Neck Surgery, Şişli Etfal Teaching and Research Hospital, Istanbul

Tülay Başak, MD

Department of Pathology, Şişli Etfal Teaching and Research Hospital, Istanbul

Case Report

A 44-year-old female presented with a left sided enlarged multiple lymph nodes. Her present medical history began 5 months prior to admission with multiple lymphadenopathy on the left side of the neck. She was treated with broad spectrum antibiotics. Lymphadenopathy persisted and enlarged. Before the admission a new antibiotic regimen was prescribed. Then the patient was referred to our unit because treatment had failed to produce improvement. Her history was significant for tobacco use and she had no history of tuberculosis infection. Her other past medical history as well as her familial histories were unremarkable.

On physical examination multiple lymph nodes were found in all levels of the left neck. Maximal diameters of the lymph nodes were 2x2 cm. Right neck was free for adenopathy. A rigid nasopharyngeal examination showed mucosal irregularity on the posterior wall of nasopharynx. Other otorhinolaryngological, general physical and pulmonary examinations were normal. Tuberculin skin test was 22 mm.

In order to evaluate the differential diagnosis of lymphadenopathy and nasopharyngeal pathology, a chest X ray, blood count and serological tests were performed. Sedimentation rate was 16mm/hour. There was no lymphocytosis in complete blood count. In microscopic examination of peripheric blood, no abnormal cell was seen. TPHA and VDRL tests were negative. Chest X-ray was performed and was normal as well.

Magnetic resonance imaging (MRI) scan centered on the nasopharynx, showed focal nodular thickening on the posterior wall of nasopharynx. Multiple lymphadenopathy was found on left sub-mandibular region, deep jugular and spinal accessory chain. Maximal diameter of the lymph nodes was 2.5x2 cm.

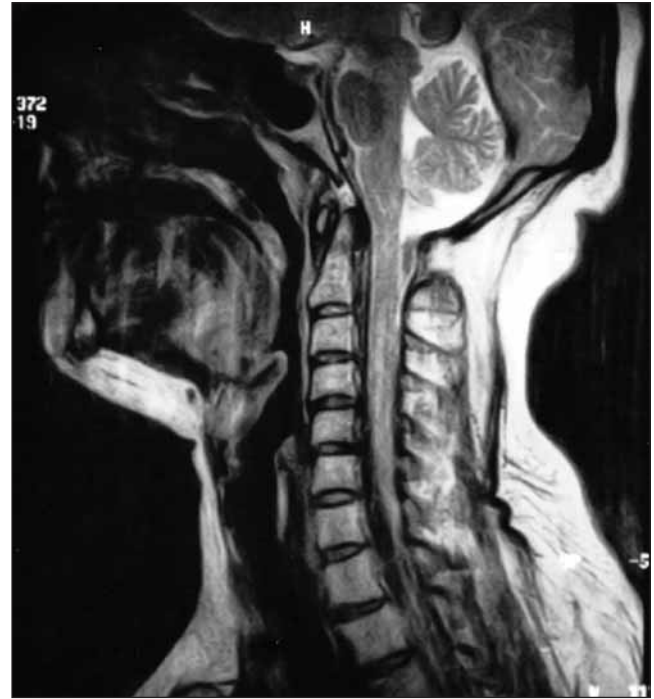

Figure 1. Sagittal T2 weighted MRI scan: Focal nodular thickening on the posterior wall of nasopharynx.

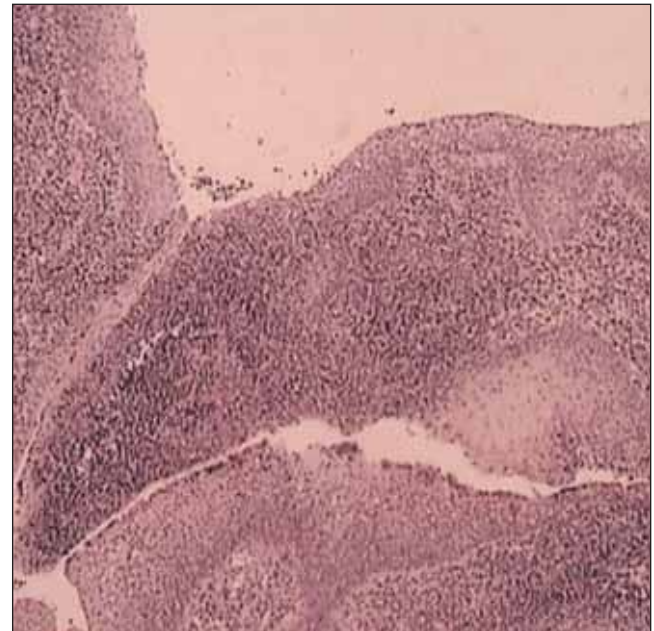


Figure 2. Mucosa lined with respiratory epithelium and under the epithelium granuloma formation could be seen in the lymphoid stroma (HE x40). [Color figure can be viewed in the online issue, which is available at www.turkarchotolaryngol.org]

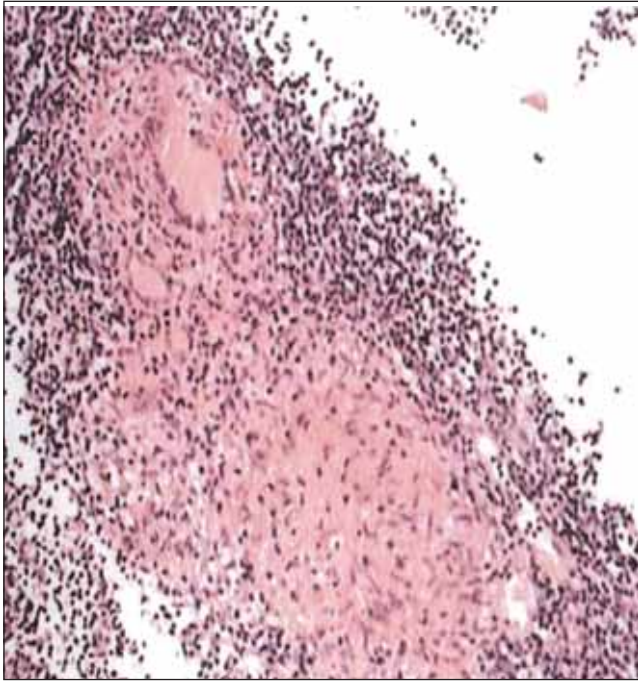


Figure 3. In the lymphoid stroma granulomatous inflammation with epithelioid histiocytes and langhans cells (HE x200). [Color figure can be viewed in the online issue, which is available at www.turkarchotolaryngol.org]

A fine-needle aspiration biopsy (FNAB) and cytology were performed. Cytokeratin stain was performed on aspirates and the result was negative. Epithelial carcinoma was excluded and lymph node biopsy was offered to make definitive diagnosis.

A neck lymph node and nasopharyngeal biopsy was performed. On pathological examination granulomatous inflammation with caseation necrosis was found. The direct examination with Ziehl-Nielsen stain was negative. polymerase chain reaction (PCR) for *M. tuberculosis* was found as positive. Culture for *M. tuberculosis* was found positive 40 days after operation as well.

An antituberculosis therapy was prescribed combining isoniazid, rifampin, pyrazinamide and ethambutol. Three months after the therapy lymph nodes resolved and the nasopharyngeal examination was normal. One year after therapy the

nasopharyngeal examination was normal and the neck was free for adenopathy.

Discussion

Nasopharyngeal tuberculosis is a rare and distinct form of tuberculosis infection. Tuberculosis infection has a worldwide increase and, still, the vast majority of the patients are seen in endemic areas such as South Asia and Africa.² Aging of population, diabetes mellitus, malignant tumors, diseases with decreased immune function such as HIV patients, socioeconomic risk groups such as homeless people will be the cause of worldwide increase.³ Although nasopharyngeal tuberculosis occurs in all decades of adult life, it has two peaks of frequency between 15-30 and 50-601 with female predominance.²

Neck node enlargement is the major presenting symptom in nasopharyngeal tuberculosis.⁴ It is usually unilateral and could be seen in all levels of the neck. Other symptoms are variable and include nasal obstruction, hearing loss, tinnitus, otalgia, postnasal drip, brisk epistaxis, altered taste and smell, snoring, facial pain, pharyngeal pain, chronic otitis media and sore throat.²

In the vast majority of the patients, nasopharyngeal tuberculosis appears as a mass lesion or mucosal irregularity. Other findings could be nasopharyngeal swelling, ulceration, whitish patch, discoloration or lymphoid hyperplasia.²

The origin of nasopharyngeal tuberculosis is still debatable. Before the advent of antituberculosis medication, secondary infection of nasopharynx from systemic or pulmonary tuberculosis was common. In 1936, Graff reviewed 118 patients with pulmonary tuberculosis and found macroscopic lesions in the nasopharynx in 36% of the cases where as this percentage was 82% for histologic tuberculosis changes.^{4,5} In 1946 Hollander reported a 75% incidence of tuberculosis in an autopsy study of 24 patients with pulmonary lesions.⁴

However in 1974 Rohwedder reviewed 843 patients with pulmonary tuberculosis and found upper respiratory system tuberculosis in 16 patients of these patients. In this report only one patient had tuberculosis of the nasopharynx.⁵ Tse et al.² reviewed 57 cases of nasopharyngeal tuberculosis and this largest report revealed that 31 of 57 cases showed no abnormality on chest X-rays. These findings emphasized that the majority of the patients with nasopharyngeal involvement occur as a primary.

The nasopharynx can be contaminated from airway, hematogenous or lymphatic seeding. All these ways are used to explain secondary tuberculosis. Nasopharyngeal contamination with infected sputum from an active lung lesion, hematogenous contamination or lymphatic contamination by rich lymphatic network of the Waldeyer ring will lead to nasopharyngeal tuberculosis.¹ On the other hand, primary tuberculosis is a result of inhalation of bacilli in airborne droplets.^{1,2}

Nasopharyngeal tuberculosis has a variable symptomatology and its differential diagnosis includes several diseases.² The problem in tuberculosis is that a patient, whose illness is not diagnosed as tuberculosis, can be a source of infection. This will be resulted with spread of infection to healthy population.³ Thus, early diagnosis is crucial. Konishi et al.³ emphasized the necessity of "suspicion" for early diagnosis. In their study, patients which suspected to have tuberculosis infection, the delay time before the accurate diagnosis is shorter than the patients who did not suspected. Therefore, in the examination of nasopharyngeal pathology, a physician should consider tuberculosis at the time of differential diagnosis.

For definitive diagnosis histopathological and microbiological confirmation of tuberculosis is essential. On histopathological examination granulomatous inflammation with caseation necrosis is

seen. Microbiological confirmation of tuberculosis is made by Ehrlich Ziehl Nielsen direct stain for acid fast bacilli and culture for *M. tuberculosis*. It must be emphasized that nasopharyngeal biopsies that showed granulomatous inflammation will be negative after direct stain for acid fast bacilli. In the literature, as in this case, this occurs in 12 out of 57 patients.² As to bacterial examination, gene analysis by PCR is better than acid-fast culture for sensitivity and rapid results.³ Konishi et al.³ reported 14 cases with *M. tuberculosis* infection, which were diagnosed histologically, in the ENT area and they were found *M. tuberculosis* by culturing acid-fast bacilli 4 out of 14 patients. They have performed PCR technique on 7 patient's biopsy materials and they were able to detect bacilli in 2 out of 7 patients. They also reported a case which was negative after culture and positive after PCR technique. In our case we both performed both EZN stain, culture of *M. tuberculosis* and PCR method. The direct examination with Ziehl-Nielsen stain was negative. PCR for *M. tuberculosis* was found as positive. Culture for *M. tuberculosis* was found positive 40 days after operation as well.

The role of FNAB in diagnosis is not yet established. As in this case, this simple technique will be used to rule out epithelial carcinoma by using cytokeratin stain. On histopathological examination, areas of granulomatous reactions, containing epithelioid and giant cells, may be seen in nasopharyngeal carcinoma.⁶ Therefore, although the FNAB suggests granulomatous reaction, Serhani and Ricabi⁶ emphasized the necessity of documenting the presence of *M. tuberculosis* in biopsy material.

Investigation of systemic or pulmonary tuberculosis must be made. Chest X-rays and skin test for *M. tuberculosis* will be useful. Differential diagnosis includes nasopharyngeal carcinoma, Wegener granulomatosis, midline granuloma, sarcoid, syphilis, leprosy, fungal infection, PAN and lymphoma.

Treatment includes triple therapy combining isoniazid, rifampicin, and ethambutol, or quadritherapy with pyrazinamide, isoniazid, rifampicin, and ethambutol. The duration of anti-tuberculosis therapy will not be less than 6 months.¹ With adequate treatment, prognosis is favorable.^{1,2,5}

In conclusion, nasopharyngeal tuberculosis is rare entity. It usually appears as a primary and the pathophysiology of primary infection is still controversial. For early detection, suspicious is crucial. Therefore, it is important to consider the tuberculosis in the differential diagnosis of nasopharyngeal pathology. Further studies and additional cases are needed to understand this rare infection and to estimate its real incidence.

References

1. **Percodani J, Braun F, Arrue P, et al.** Nasopharyngeal tuberculosis. *J Laryngol Otol* 1999; 113: 928-31.
2. **Tse GM, Ma TK, Chan AB, et al.** Tuberculosis of the nasopharynx: a rare entity revisited. *Laryngoscope* 2003; 113: 737-40.
3. **Konishi K, Yamane H, Iguchi H, et al.** Study of tuberculosis in the field of otorhinolaryngology in the past 10 years. *Acta Otolaryngol Suppl* 1998; 538: 244-9
4. **Mair IW, Johannessen TA.** Nasopharyngeal tuberculosis. *Arch Otolaryngol* 1970; 92: 392-3.
5. **Chopra RK, Kerner MM, Calcaterra TC.** Primary nasopharyngeal tuberculosis: a case report and review of this rare entity. *Otolaryngol Head Neck Surg* 1994; 111: 820-3.
6. **al Serhani, AM, al Rilcabi AC, Assiry MA.** Primary nasopharyngeal tuberculosis: Case report and review of the literature. *Ear Nose Throat J* 1997; 76: 41-2.
7. **Aktan B, Selimoğlu E, Üçüncü H, Sütbeyaz Y.** Primary nasopharyngeal tuberculosis in a patient with the complaint of snoring. *J Laryngol Otol* 2002; 116: 301-3.

Conflict of interest statement:

No conflicts declared.

Correspondence: Şenol Civelek, MD

Darıüşşafakka Mah. Karikatüristler Sitesi

C Blok No: 14 İstinye / İSTANBUL

Phone: +90 532 455 50 28

Fax: +90 212 531 85 16

e-mail: scivelek@hotmail.com