







Nasopharyngeal Glial Heterotopia with Intracranial Extension: A Case Report

İntrakraniyal Uzanımlı Nazofarengeal Glial Heterotopi: Olgu Sunumu

Ozan Gökler¹ , Işıl Karanfil¹ , İlker Koçak¹ , Muzaffer Ozan Altuntaş¹ , Ayşe Armutlu² ,
Ömer Faruk Ünal¹ 

¹Department of Otorhinolaryngology, Koç University Hospital, İstanbul, Turkey

²Department of Pathology, Koç University Hospital, İstanbul, Turkey

Case Report

Olgu Sunumu

Abstract

Nasopharyngeal glial heterotopia is a mass composed of mature neural tissue occurring outside the central nervous system and is extremely rare. The preoperative diagnosis of such a mass in the head and neck region is challenging. In this study, we report a case of a 16-month-old patient presenting with respiratory distress and snoring caused by nasopharyngeal glial heterotopia. Radiologic imaging and histopathology are obligatory for the definitive diagnosis of glial heterotopia. Preoperative evaluation of an intracranial

connection is one of the most essential issues in the presence of pediatric nasopharyngeal masses. The gold standard of treatment is surgical excision. Early recognition and early surgical excision by endoscopic or external approach are crucial to relieve respiratory distress and to maintain healthy growth and development.

Keywords: Nasopharynx, glial heterotopia, pediatric, respiratory distress



Öz

Nazofarengeal glial heterotopi, matür nöral sinir dokusundan gelişen ve merkezi sinir sistemi dışında görülen oldukça nadir bir kitledir. Baş-boyun bölgesinde yerleşen bu kitlenin preoperatif tanısı zordur. Bu çalışmada, nazofarengeal glial heterotopinin neden olduğu solunum sıkıntısı ve horlama ile başvuran 16 aylık bir hasta sunduk. Radyolojik görüntüleme ve histopatoloji glial heterotopinin kesin tanısı için zorunludur. Preoperatif kafa içi bağlantısının değerlendirilme-

si pediatrik nazofarengeal kitlelerin varlığında en önemli yapılabraklardan biridir. Tedavide altın standart cerrahi eksizyondur. Erken tanı ve erken endoskopik veya eksternal yaklaşımla cerrahi eksizyon, solunum sıkıntısını gidermek ve çocukta sağlıklı büyüme ve gelişmeyi sağlamak açısından çok önemlidir.

Anahtar kelimeler: Nazofarenks, glial heterotopi, pediatrik, solunum güçlüğü

ORCID IDs of the authors:

O.G. 0000-0003-1621-3687;
I.K. 0000-0002-8383-6115;
İ.K. 0000-0001-8636-3934;
M.O.A. 0000-0002-8747-7420;
A.A. 0000-0001-9804-0454;
Ö.F.Ü. 0000-0001-5692-2475.

Cite this article as:

Gökler O, Karanfil I, Koçak I, Altuntaş MO, Armutlu A, Ünal ÖF. Nasopharyngeal Glial Heterotopia with Intracranial Extension: A Case Report. Turk Arch Otorhinolaryngol 2018; 56(3): 177-9.

This study was presented at the 4th Congress of European ORL-HNS, October 9, 2017, Barcelona, Spain.

Bu çalışma, 4. Avrupa Otorinolarenoloji - Baş Boyun Cerrahisi kongresi'nde sunulmuştur, 9 Ekim 2017, Barselona, İspanya.

Corresponding Author/Sorumlu Yazar:

Ozan Gökler; ogokler@kuh.ku.edu.tr

Received Date/Geliş Tarihi: 09.01.2018

Accepted Date/Kabul Tarihi: 20.04.2018

© Copyright 2018 by Official Journal of the Turkish Society of Otorhinolaryngology and Head and Neck Surgery Available online at www.turkarchotolaryngol.net

© Telif Hakkı 2018 Türk Kulak Burun Boğaz ve Baş Boyun Cerrahisi Derneği Makale metnine www.turkarchotolaryngol.net web sayfasından ulaşılabilir.

DOI: 10.5152/tao.2018.3204

Introduction

Glial heterotopia is a non-neoplastic, extracranial midline malformation. Nasal glioma is the most frequently encountered entity among congenital nasal masses, which are seen in one in 20,000–40,000 live births (1). It consists of differentiated neuroectodermal tissue outside the central nervous system (2). Clinicians may commonly consider adenoid hypertrophy as the cause for the complaints of nasopharyngeal obstruction and feeding difficulties in infants and older children; however, nasopharyngeal glial heterotopias may also mimic this presentation. The most common age for diagnosis is the newborn period or early childhood (3). A recent literature review revealed that glial heterotopia may lead to upper airway obstruction,

which is reported to occur in 48.6% of 181 patients with glial heterotopia in the head and neck (4).

The differential diagnoses primarily include lymphovascular malformations, encephalocele, and teratomas; glial heterotopias can be differentiated from other uncommon congenital pharyngeal masses in children with the guidance of radiologic and especially histopathologic examinations. In case of glial heterotopia, prior to surgery, the possibility of intracranial connection with the mass should be ruled out by magnetic resonance imaging (MRI).

The origin of glial heterotopia is hypothesized to be due to the following: (i) an encephalocele that

lost its connection with the subarachnoid space, (ii) the differentiation of multipotent cells into mature neuroectodermal cells outside the central nervous system during embryogenesis, and (iii) sequestered glial cells of the olfactory bulb (5).

We aim to discuss our case with a rare presentation of nasopharyngeal glial heterotopia to attract attention to the diagnostic workup in children with respiratory obstruction due to a congenital mass in the head and neck.

Case Presentation

A 16-month-old, Caucasian, male patient presented to the otolaryngology outpatient clinic with a history of respiratory distress and snoring. On physical examination, a mass that extended from the left side of the nasopharynx to the parapharyngeal space causing deviation of the uvula toward the contralateral side was observed. The patient was found to have no dysmorphic features. Furstenberg test was negative. MRI revealed a multiloculated, dominantly cystic lesion in the left parapharyngeal space on T2-weighted images and no enhancement on T1-weighted images with contrast (Figure 1). No apparent intracranial connection was reported.

These findings indicated a provisional diagnosis of cystic masses, lymphatic malformations, encephalocele, and glial heterotopia. Subsequently, the diagnosis of glial heterotopia was confirmed by biopsy, which revealed neuroglial tissue that strongly stained with glial fibrillary acidic protein in immunohistochemistry. The

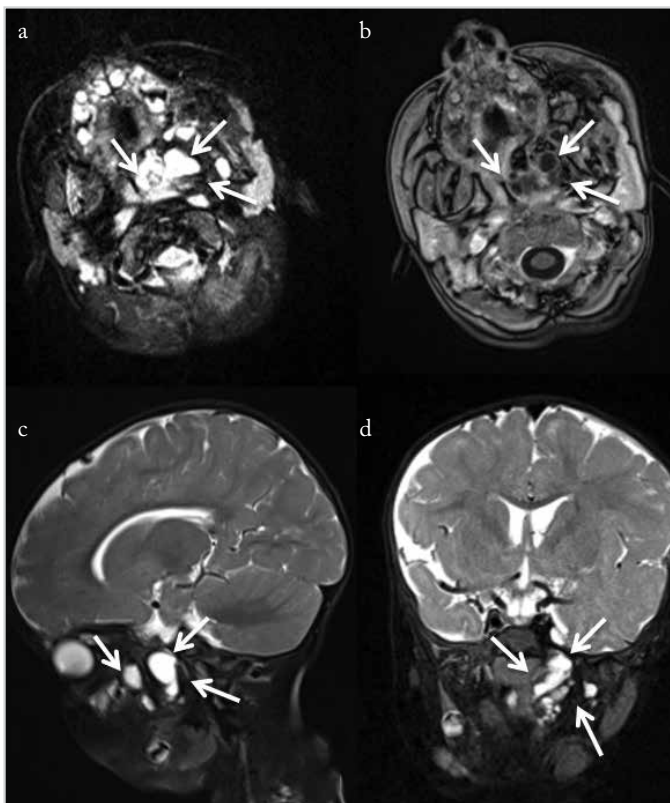


Figure 1. a-d. Multiloculated dominantly cystic lesion on the left parapharyngeal space was revealed on a T2-weighted axial plane (a), sagittal plane (c), and coronal plane (d). No contrast enhancement was detected on T1-weighted axial image (b)

mass was excised by a transoral approach, dissecting laterally to the medial pterygoid plate and superiorly in the region of the pterygoplatine fossa. In the course of the dissection, intracranial extension through occipital foramen was recognized, and to leave a minimal amount of residual mass was the final decision. The definitive histopathologic examination was compatible with glial heterotopia (Figures 2, 3). The complaints of the patient completely resolved following the surgery, and further growth and development was normal. The recovery period was unremarkable after 23 months of follow-up.

Discussion

Nasopharyngeal glial heterotopia is an extremely rare benign developmental malformation according to the statistical results of a review about glial heterotopia cases between 1961 and 2009 (4). Considering the very early age of presentation, extremely rare location involving nasopharyngeal space, and presence of an intracranial connection, our report is distinguishable from other cases of parapharyngeal glial heterotopia in the literature.

The presenting signs and symptoms depend on the location of the glial heterotopia. Our patient had a chief complaint of

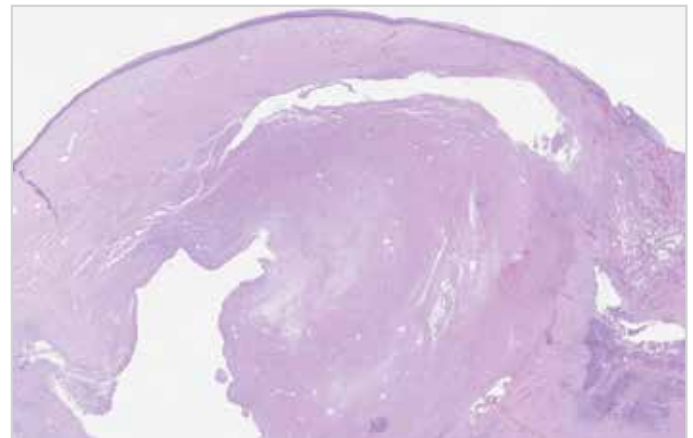


Figure 2. Neuroglial tissue under squamous epithelium (hematoxylin and eosin, original magnification X40)

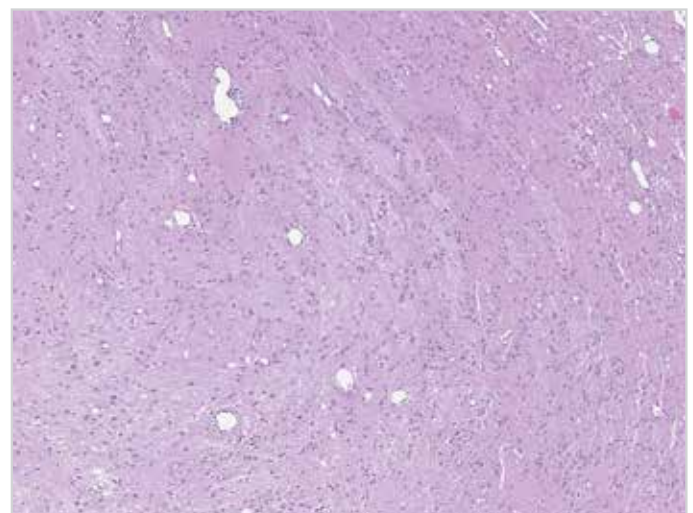


Figure 3. Neuroglial fibrils and astrocytes (hematoxylin and eosin, original magnification X200)

nasopharyngeal airway obstruction. The presentation imitates common adenoid hypertrophy. Structural etiology such as common congenital malformations of the head and neck should be evaluated during the diagnostic process. Glial heterotopia can be associated with cleft palate, micrognathia, and Pierre Robin syndrome (5). Our case did not exhibit these reported anomalies revealed by otolaryngologic and endoscopic examinations.

Although visualization via nasopharyngoscopy and MRI complemented by computed tomography (CT) is recommended in the diagnostic workup of a parapharyngeal mass (6), CT was not performed in our case as preoperative MRI and biopsy results confirmed the primary diagnosis of glial heterotopia and directed the decision to excise the malformation. In addition, we preferred not to expose a 16-month-old patient to radiation through CT, considering the alternative approaches available.

To relieve airway obstruction, the gold-standard treatment for glial heterotopia is surgical resection. Possible alternatives for surgery are transoral, which was performed in our case, endoscopic, and external transcervical approaches (7). The use of these methods varies according to different locations of glial heterotopia. Surgery aims complete resection of the mass. However, this goal may not be feasible in cases such as ours owing to the presence of an intracranial connection. Recurrence is seen in 4%-10% of the patients after incomplete excision, but slow proliferation characteristic of the malformation may allow the surgeon to follow the patient and plan additional surgical interventions in the future follow-up of the patient (8). We plan to examine our patient with nasopharyngoscopy every 3 months. The examinations showed a healthy upper airway and a healthy growth and development in all follow-up visits with the last one at 23 months post-operatively. We have obtained an MRI at postoperative first year which ruled out the recurrence of the malformation.

Conclusion

We reviewed a pediatric case with nasopharyngeal mass to remind the clinicians of the significance of considering glial heterotopia in the differential diagnosis for a mass in the head and neck. The existence of an intracranial connection should be investigated prior to the surgery. Early recognition and early surgical resection by endoscopic or external approach are crucial to relieve respiratory distress and to maintain healthy growth and development in the pediatric patient.

Informed Consent: Written informed consent was obtained from the parents of the patient.

Peer-review: Externally peer-reviewed.

Author Contributions: Concept - O.G., I.K., İ.K., M.O.A., A.A., Ö.F.Ü.; Design - O.G., I.K., İ.K., M.O.A., A.A., Ö.F.Ü.; Supervision - O.G., I.K., İ.K., M.O.A., A.A., Ö.F.Ü.; Resource - O.G., Ö.F.Ü.; Materials - A.A.; Data Collection and/or Processing - I.K., İ.K., M.O.A.,

A.A.; Analysis and/or Interpretation - İ.K., M.O.A., A.A., Ö.F.Ü.; Literature Search - O.G., I.K., M.O.A.; Writing - O.G., I.K.; Critical Reviews - O.G., I.K., İ.K., M.O.A., A.A., Ö.F.Ü.

Conflict of Interest: The authors have no conflicts of interest to declare.

Financial Disclosure: The authors declared that this study has received no financial support.

Hasta Onamı: Hastanın ebeveyninden yazılı onam alınmıştır.

Hakem Değerlendirmesi: Dış bağımsız.

Yazar Katkıları: Fikir - O.G., I.K., İ.K., M.O.A., A.A., Ö.F.Ü.; Tasarım - O.G., I.K., İ.K., M.O.A., A.A., Ö.F.Ü.; Denetleme - O.G., I.K., İ.K., M.O.A., A.A., Ö.F.Ü.; Kaynaklar - O.G., Ö.F.Ü.; Gereçler - A.A.; Veri Toplanması ve/veya İşlemesi - I.K., İ.K., M.O.A., A.A.; Analiz ve/veya Yorum - İ.K., M.O.A., A.A., Ö.F.Ü.; Literatür Taraması - O.G., I.K., M.O.A.; Yazıyı Yazan - O.G., I.K.; Eleştirel İnceleme - O.G., I.K., İ.K., M.O.A., A.A., Ö.F.Ü.

Çıkar Çatışması: Yazarlar çıkar çatışması bildirmemişlerdir.

Finansal Destek: Yazarlar bu çalışma için finansal destek almadıklarını beyan etmişlerdir.

References

1. Clarós P, Bandos R, Clarós A Jr, Gilea I, Clarós A, Real M. Nasal gliomas: main features, management and report of five cases. *Int J Pediatr Otorhinolaryngol* 1998; 46: 15-20. [CrossRef]
2. Chen CY, Huang JH, Choi WM, Chen CL, Chan WP. Parapharyngeal neuroglial heterotopia presenting as a growing single locular cyst: MR imaging findings. *AJNR Am J Neuroradiol* 2005; 26: 96-9.
3. Haloob N, Pepper C, Hartley B. A series of parapharyngeal glial heterotopia mimicking lymphatic malformation. *Int J Pediatr Otorhinolaryngol* 2015; 79: 1975-9. [CrossRef]
4. Melo GM, Goncalves Gdo N, Souza RA, Sguillar DA. Extensive parapharyngeal and skull base neuroglial ectopia; a challenge for differential diagnosis and treatment: case report. *Sao Paulo Med J* 2010; 128: 302-5. [CrossRef]
5. Longo D, Menchini L, Delfino LN, Lozzi S, Seganti G, Diomedes-Camassei F, et al. Parapharyngeal neuroglial heterotopia in Pierre Robin sequence: MR imaging findings. *Int J Pediatr Otorhinolaryngol* 2009; 73: 1308-10. [CrossRef]
6. Hu J, Ta J, Deisch J, Lee S, Wareham R. Image-guided transoral resection of recurrent parapharyngeal space glial heterotopia. *Int J Pediatr Otorhinolaryngol* 2014; 78: 366-9. [CrossRef]
7. Prado-Calleros HM, Arrieta-Gómez JR, Castillo-Ventura B, Martínez SP, Jiménez-Gutiérrez C, Jiménez-Escobar I. Myocutaneous sternocleidomastoid flap for reconstruction after the resection of a parapharyngeal heterotopic glioma in a child with cleft palate, and systematic review of parapharyngeal glial heterotopia. *Int J Pediatr Otorhinolaryngol* 2016; 81: 51-4. [CrossRef]
8. Dasgupta NR, Bentz ML. Nasal gliomas: identification and differentiation from hemangiomas. *J Craniofac Surg* 2003; 14: 736-8. [CrossRef]