

Coincidental Killian-Jamieson Diverticulum During Thyroid Surgery: A Rare Cause of Dysphagia

Disfajinin Nadir Bir Nedeni: Tiroid Cerrahisi Sırasında Rastlantısal Killian-Jamieson Divertikülü

Case Report Olgu Sunumu

Gülezer Saylam¹, Kemal Keseroğlu¹, Ömer Bayır¹, Emel Çadallı Tatar¹, Mehmet Hakan Korkmaz²

¹Department of Otolaryngology, Dışkapı Yıldırım Beyazıt Training and Research Hospital, Ankara, Turkey

²Department of Otolaryngology, Yıldırım Beyazıt University School of Medicine, Ankara, Turkey

Abstract

The aim of this case report is to demonstrate a very rare coincidental existence and management of the Killian-Jamieson diverticulum during thyroid surgery in a patient with dysphagia. An 18-year-old female patient with the complaints of progressive dysphagia and a rapidly growing mass at the anterior cervical region was undergone thyroid lobectomy. Coincidentally, a 2x2 cm Killian-Jamieson diverticulum was observed and simultaneously excised with the thyroid lobe, preserving

the recurrent laryngeal nerve. Dysphagia is a frequent symptom, especially in patients with a rapidly growing thyroid mass. Thyroid surgeons should keep in mind that hypopharyngeal and upper esophageal pathologies can mimic the symptoms of a thyroid mass; therefore, detailed imaging techniques should be used for the differential diagnosis.

Keywords: Dysphagia, Killian-Jamieson diverticulum, thyroid lobectomy

Öz

Bu olgu sunumunun amacı, disfaji semptomlu bir hastada tiroid cerrahisi sırasında rastlantısal olarak çok nadir görülen Killian-Jamieson divertikülünün varlığı ve tedavisinin gösterilmesidir. 18 yaşında kadın hastaya, progresif disfaji ve ön servikal bölgede hızlı büyüyen kitle nedeniyle tiroid nodülü tanısı ile tiroid lobektomisi uygulandı. Rastlantısal olarak 2x2 cm'lik Killian-Jamieson divertikül ile karşılaşıldı ve rekürren larengal sinir korunarak tiroid lobu ile birlikte eksize

edildi. Disfaji özellikle hızlı büyüyen tiroid kitlelerinde sık görülen bir semptomdur. Tiroid cerrahları, hipofarengal ve üst özofageal patolojilerin tiroid kitlesine benzer semptomlar gösterebileceğini unutmamalıdır; bu yüzden ayırıcı tanı için ayrıntılı görüntüleme teknikleri kullanılmalıdır.

Anahtar Kelimeler: Disfaji, Killian-Jamieson divertikülü, tiroid lobektomi

Introduction

Dysphagia is termed as difficulty in swallowing and divided into oropharyngeal and esophageal types according to its anatomic localization (1). An esophageal diverticulum is an anatomical and structural disorder that is of either pulsion or traction type, resulting mainly in dysphagia and also regurgitation, aspiration, cough, and halitosis (2). However, the most common type of diverticulum in the upper segment is the Zenker's diverticulum; the Killian-Jamieson (K-J) type is seen very rarely but has a significant anatomical relationship with the recurrent laryngeal nerve (RLN) (3).

The aim of this report is to show the possible coincidental causes of dysphagia, as seen in the K-J di-

verticulum before thyroid surgery in patients with prominent dysphagia.

Case Report

An 18-year-old female patient with the complaints of a rapidly progressive growing mass in the anterior cervical region and dysphagia since a year was referred to our clinic. During physical examination, the right lobe of her thyroid gland was diffusely palpable, and there was no lymphadenopathy with palpation in her bilateral neck regions. Ultrasonographic examination revealed a complex echogenic 19x30x42-mm single nodule with partial halo in the right thyroid lobe and no cervical pathologic lymphadenopathy. Benign cytology was noted in the fine-needle aspiration biopsy results. There were no



This study was presented at the 11th International Congress of Otorhinolaryngology and Head Neck Surgery, 17-19 April 2014, Ankara, Turkey.

Bu çalışma, 11. Uluslararası Kulak Burun Boğaz ve Baş Boyun Cerrahisi Kongresi'nde sunulmuştur, 17-19 Nisan 2014, Ankara, Türkiye.

Address for Correspondence/Yazışma Adresi:
Kemal Keseroğlu
E-mail: keseroglukemal@yahoo.com

Received Date/Geliş Tarihi: 02.07.2016
Accepted Date/Kabul Tarihi: 06.09.2016

© Copyright 2016 by Official Journal of the Turkish Society of Otorhinolaryngology and Head and Neck Surgery Available online at www.turkarchotorhinolaryngol.org

© Telif Hakkı 2016 Türk Kulak Burun Boğaz ve Baş Boyun Cerrahisi Derneği Makale metnine www.turkarchotorhinolaryngol.org web sayfasından ulaşılabilir.

DOI: 10.5152/tao.2016.1807

suspicious ultrasound imaging and flexible laryngoscopy findings of a diverticulum. Intraoperatively, after the identification of RLN, the right lobe was completely dissected with the isthmus. The nerve was pushed anterolaterally by a 2×2 cm bulging mass originating from the lateral side of the esophagus. This mass was fluctuating, cystic but adherent to the nerve and surrounding tissues (Figure 1). It was delicately dissected from the nerve and surrounding soft

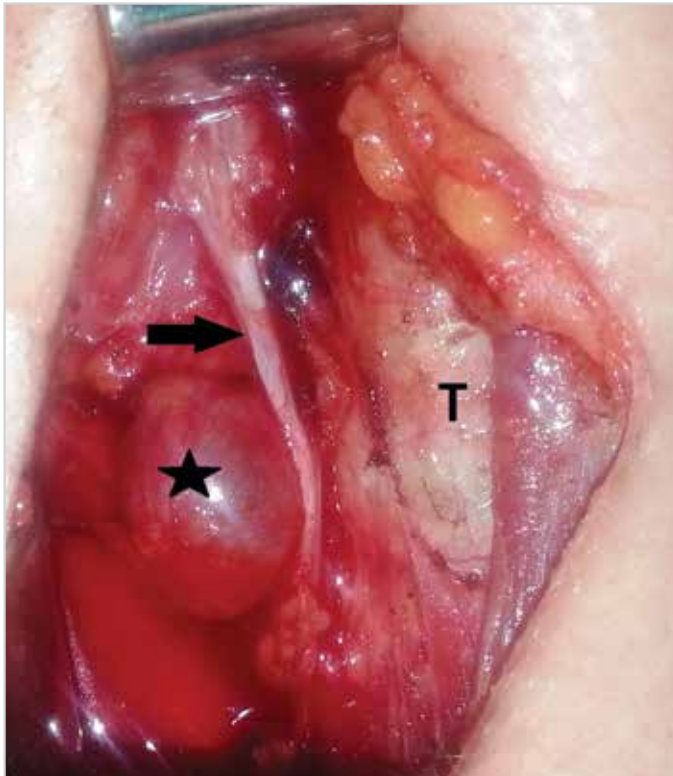


Figure 1. Appearance of the K-J diverticulum after right thyroid lobectomy (T: trachea; black asterisk: diverticulum; black arrow: recurrent laryngeal nerve)

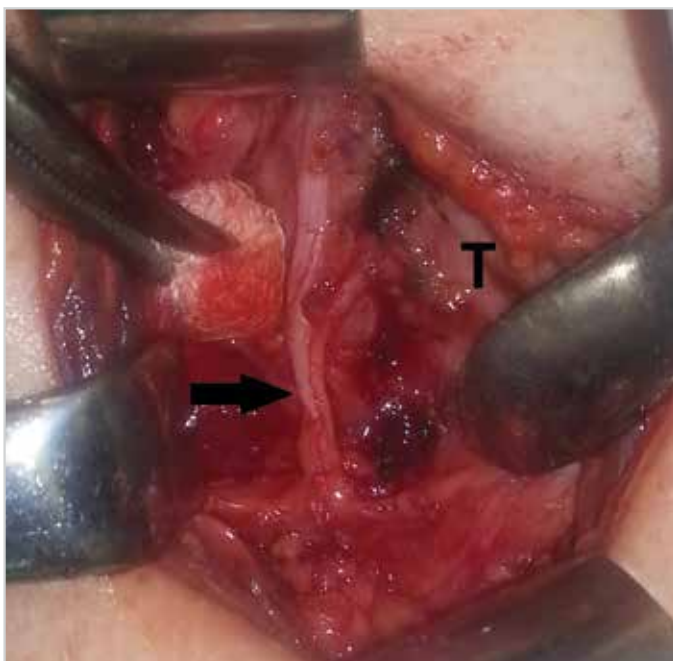

Figure 2. Appearance after excision of the diverticulum (T: trachea; black arrow: recurrent laryngeal nerve)

tissues. After skeletonization, it was seen that the mass was originating from the inferior border of cricopharyngeus muscle. It was diagnosed as a diverticulum after needle aspiration of air. The diverticulum was completely resected, and the mucosal defect was primarily sutured (Figure 2). During the postoperative period, no vocal cord palsy was seen. After 3 days of nasogastric feeding, oral alimentation was started. Dysphagia disappeared two weeks after surgery. Histopathological examination of lobectomy was papillary thyroid carcinoma and histopathological examination of the diverticulum material revealed false diverticulum without a muscular layer. Barium esophagography showed neither stenosis nor recurrence of diverticulum after one year of follow-up (Figure 3). Informed consent was obtained to use intraoperative photographs, documents, and barium X-ray images for the case report from the patient.

Discussion

Swallowing is a complex reflex comprising voluntary and involuntary phases. It involves a sophisticated organization of sensorial input of the cranial nerves and motor output by the upper aerodigestive system muscles (1). Any structural or neurological defect in this organization results in dysphagia.

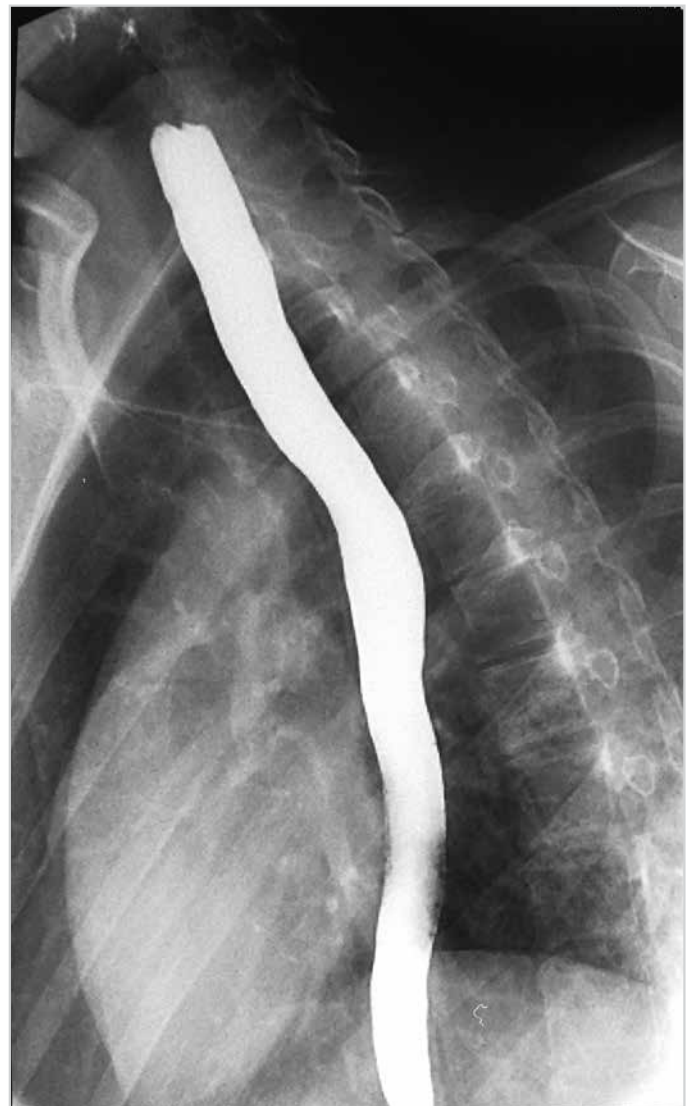

Figure 3. Barium esophagography after a 1-year follow-up

For differential diagnosis, a detailed history by asking some specific questions can be adequate to look for the anatomical localization of the etiology. Postnasal regurgitation, cough, repetitive swallowing, pain, weight loss, and reflux are significant featuring symptoms of dysphagia for determining the level of pathology (2).

The relationship between thyroid pathology and dysphagia is generally mechanical because of compression symptoms. Moreover, hypothyroidism causing esophageal motility disorder and hyperthyroidism causing myopathy are the other less common factors (4).

Esophageal diverticulum is a very rare cause of dysphagia. It is encountered in less than 1% of esophagoscopies (2). Although Zenker's diverticulum is more common and originates from the weak triangular area (Killian's dehiscence) above the cricopharyngeus muscles, the Killian-Jamieson type is rarer and less symptomatic and originates from the lateral wall of the esophagus under the cricopharyngeus muscles (Killian-Jamieson area) and protrudes anterolaterally (5). It was first described by Ekberg and Nylander in 1983 as a proximal lateral cervical esophageal diverticula (6). In a study comprising 16 K-J diverticula patients, 75% were unilateral left sided and 25% were bilateral. The average dimension was 1.4 cm (6). In this case, the K-J diverticulum was surgically diagnosed because of its typical anatomical localization originating from the esophagus under the cricopharyngeus muscles and bulging anterolaterally and having a closer relationship with RLN. Surgical treatment of K-J diverticula is transcervical because of its very close relationship with RLN (5). Fifty-eight percent of patients with diverticulum were found to be asymptomatic (6). Therefore, in general, they are incidentally diagnosed, as seen in our case. Dysphagia was considered to have occurred as a result of a rapidly growing 42-mm thyroid nodule, and there were no other symptoms of the diverticulum. As a result, no further investigation was performed. However, surgeons should suspect of other possible causes of dysphagia in thyroid patients, especially in those with prominent dysphagia and coexisting symptoms, and should collaborate with the radiologist because an experienced radiologist can distinguish a thyroid nodule from a diverticulum. Change in sonographic appearance by compression, swallowing, and repetitive examination and presence of air-fluid level are some specific ultrasound findings to differentiate a diverticulum from a thyroid nodule (7). Therefore, repetitive ultrasonography should be performed to rule out diverticulum from the thyroid nodule. Although halitosis is one of the most frequent symptoms of diverticulum, our patient showed only symptoms of dysphagia. Because of lesser symptomatic nature of the K-J diverticulum, closer relationship with RLN, and typical anterolateral protruding pattern of the diverticulum under the cricopharyngeus muscles seen in our case, Zenker's diverticulum was ruled out. Moreover, Zenker's diverticulum usually arises from the Killian's triangle present between the inferior constrictor and cricopharyngeus muscles and outpouching posteriorly (8). However, preoperative esophagography should be performed to differentiate them.

Carcinoma of the pharyngeal diverticula has an incidence of 0.3-8% in literature (9). Therefore, careful histopathological examination is necessary to diagnose the malignancy. Further computerized tomography scan and magnetic resonance imaging should be performed for the planning of treatment (9). Although the K-J diverticulum can mimic ultrasonographic features

of a thyroid nodule, there are only two reports with synchronous thyroid pathology and K-J diverticula, and there is no report on such a young patient with a K-J diverticulum in literature (3, 10).

Conclusion

In this case, dysphagia was thought to have occurred because of the rapidly growing thyroid mass, and there was no suspicion of a diverticulum based on the ultrasound findings; therefore, no further studies were conducted. If dysphagia exists with thyroid pathologies, physicians should consider the other etiologies. Detailed imaging studies should be performed before surgery not to encounter incidental copathologies that can result in undesirable complications.

Informed Consent: Written informed consent was obtained from patient who participated in this study.

Peer-review: Externally peer-reviewed.

Author contributions: Concept - G.S.; Design - G.S.; Supervision - M.H.K.; Resource - K.K.; Materials - K.K., Ö.B.; Data Collection and/or Processing - K.K.; Analysis and/or Interpretation - Ö.B., E.Ç.T.; Literature Search - Ö.B.; Writing - K.K.; Critical Reviews - M.H.K., E.Ç.T.

Conflict of Interest: No conflict of interest was declared by the authors.

Financial Disclosure: The authors declared that this study has received no financial support.

Hasta Onamı: Yazılı hasta onamı bu çalışmaya katılan hastadan alınmıştır.

Hakem Değerlendirmesi: Dış bağımsız.

Yazar Katkıları: Fikir - G.S.; Tasarım - G.S.; Denetleme - M.H.K.; Kaynaklar - K.K.; Gereçler - K.K., Ö.B.; Veri Toplanması ve/veya İşlemesi - K.K.; Analiz ve/veya Yorum - Ö.B., E.Ç.T.; Literatür Taraması - Ö.B.; Yazıyı Yazan - K.K.; Eleştirel İnceleme - M.H.K., E.Ç.T.

Çıkar Çatışması: Yazarlar çıkar çatışması bildirmemişlerdir.

Finansal Destek: Yazarlar bu çalışma için finansal destek almadıklarını beyan etmişlerdir.

References

1. Schindler JS, Kelly JH. Swallowing disorders in the elderly. *Laryngoscope* 2002; 112: 589-602. [[CrossRef](#)]
2. Thomas ML, Anthony AA, Fosh BG, Finch JG, Maddern GJ. Oesophageal diverticula. *Br J Surg* 2001; 88: 629-42. [[CrossRef](#)]
3. Mimatsu K, Oida T, Kano H, Kawasaki A, Fukino N, Kida K, et al. Killian-Jamieson diverticula presenting synchronously with thyroid adenoma. *Case Rep Gastroenterol* 2013; 7: 188-94. [[CrossRef](#)]
4. Ebert EC. The thyroid and the gut. *J Clin Gastroenterol* 2010; 44: 402-6. [[CrossRef](#)]
5. Andrews K, Branski RC, Amin MR. Progressive dysphagia and cough. *Dysphagia* 2013; 28: 595-7. [[CrossRef](#)]
6. Rubesin SE, Levine MS. Killian-Jamieson diverticula: radiographic findings in 16 patients. *AJR Am J Roentgenol* 2001; 177: 85-9. [[CrossRef](#)]
7. Pang JC, Chong S, Na HI, Kim YS, Park SJ, Kwon GY. Killian-Jamieson diverticulum mimicking a suspicious thyroid nodule: sonographic diagnosis. *J Clin Ultrasound* 2009; 37: 528-30. [[CrossRef](#)]
8. Ferreira LE, Simmons DT, Baron TH. Zenker's diverticula: pathophysiology, clinical presentation, and flexible endoscopic management. *Dis Esophagus* 2008; 21: 1-8.
9. Khan AS, Dwivedi RC, Sheikh Z, Khan S, Dwivedi RC, Kanwar N, et al. Systematic review of carcinoma arising in pharyngeal diverticula: a 112-year analysis. *Head Neck* 2014; 36: 1368-75. [[CrossRef](#)]
10. Kim MH, Kim EK, Kwak JY, Kim MJ, Moon HJ. Bilateral Killian-Jamieson diverticula incidentally found on thyroid ultrasonography. *Thyroid* 2010; 20: 1041-2. [[CrossRef](#)]